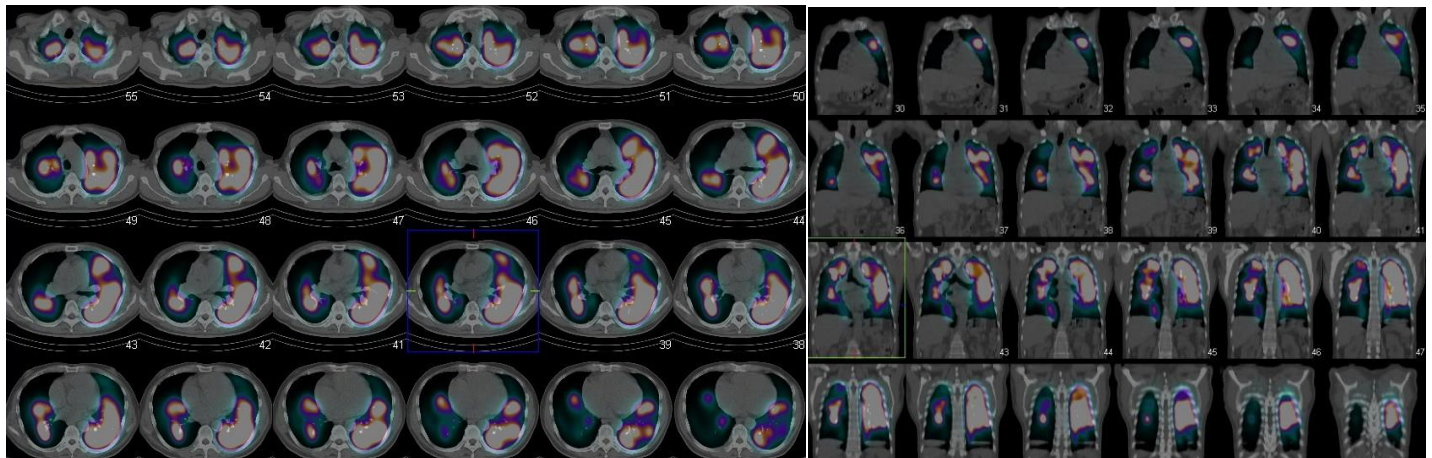
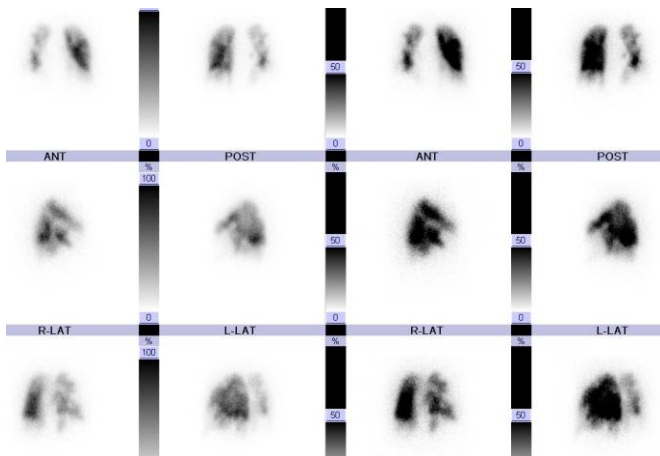


# Case 1605YT

60s-year old man

- Chief complaint: Exertional dyspnea
- Clinical history: He experienced exertional dyspnea, cough and loss of appetite since January 200X. When he consulted a medical doctor in March, cardiomegaly and liver dysfunction were found.
- Tc-99m MAA



- Chest X-ray CT

