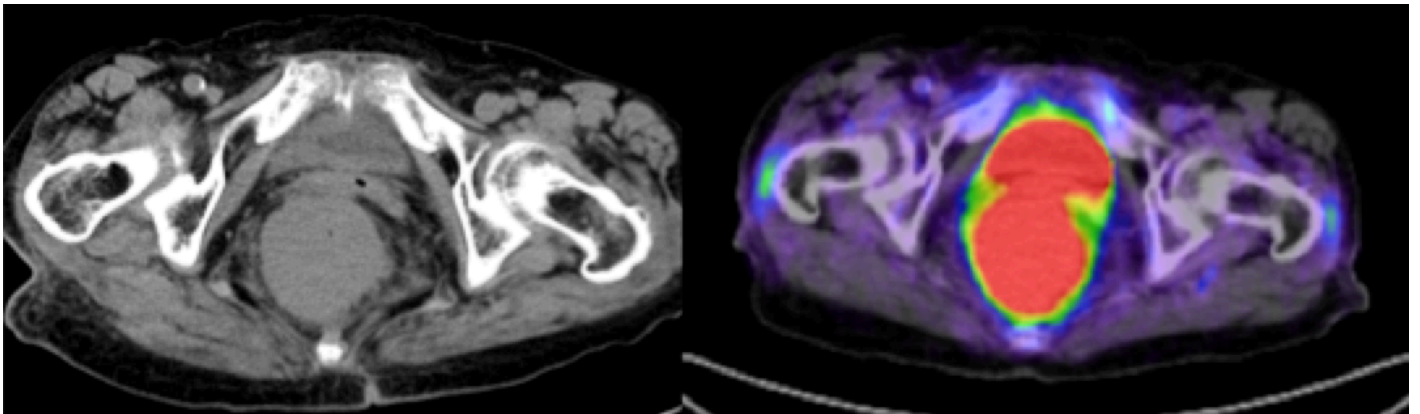


Case 1605NK-1,2

- Two patients with rectal tumor are presented.
- Case 1: 80s-year old
- FDG-PET CT
 - SUV max=14.2



- Case 2: 70s-year old
- FDG-PET CT
 - SUV max=7.4

