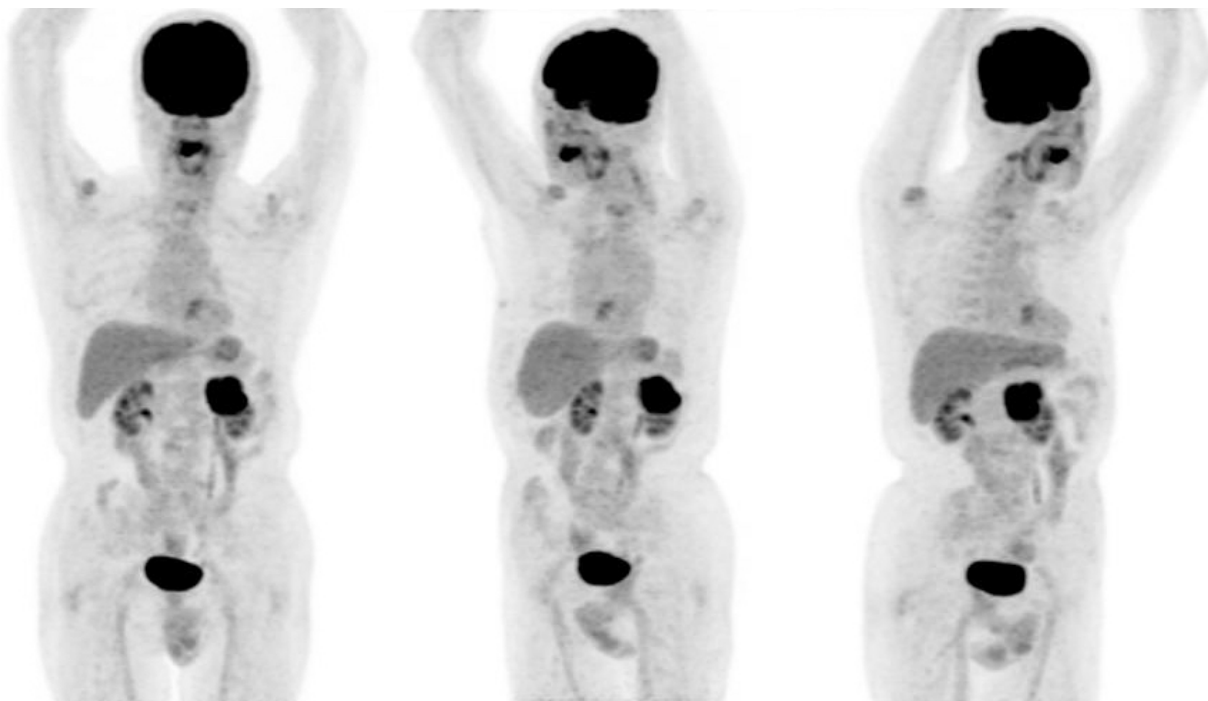


## Case 1605MT

70s-year old man

- Chief complaint: high CEA level
- Clinical course: He had rectal cancer and surgically removed 10 years ago. While CEA was normal by April, 201X, it was increased to 23 ng/mL in November. FD-PET was performed for the closer examination.
- MIP image



- Fusion images

