

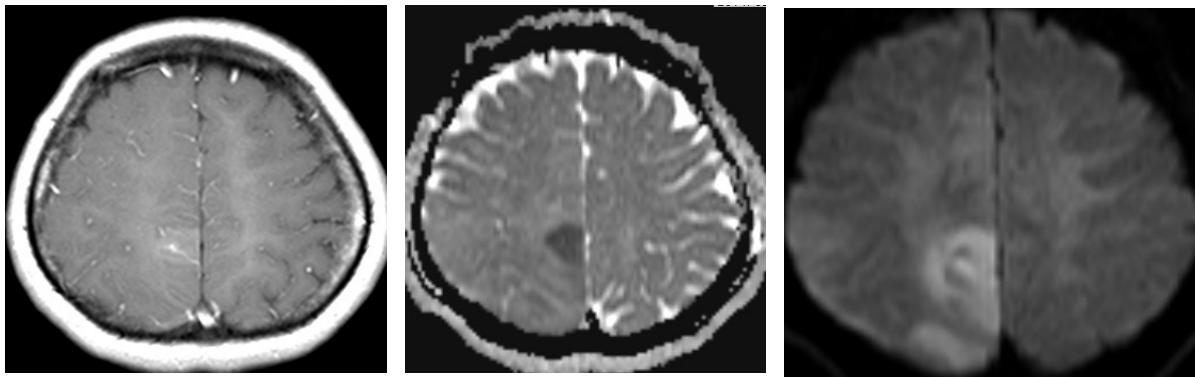
## Case 1505YT

50s-year old female

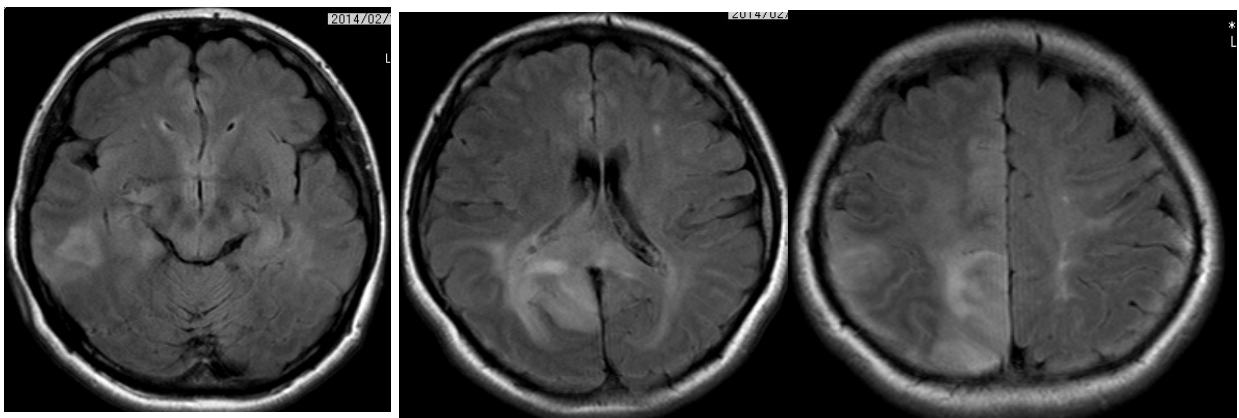
- Chief complaint: abnormal MRI findings during follow-up studies
- Past history: She had history of cerebral venous thrombosis three years ago and has been followed up regularly with MRI. Abnormal findings were found in the MRI images.
- Imaging data presented will be T2 weighted, FLAIR, T1-contrast enhanced, T2\*, SWI, MR venography, MRS, and TI-201 SPECT

- T1 weighted CE

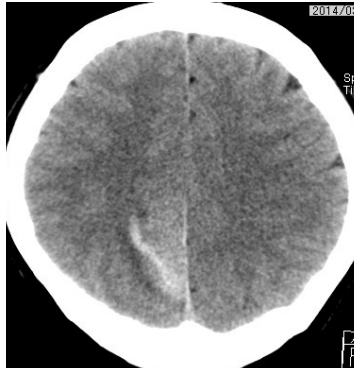
MR diffusion



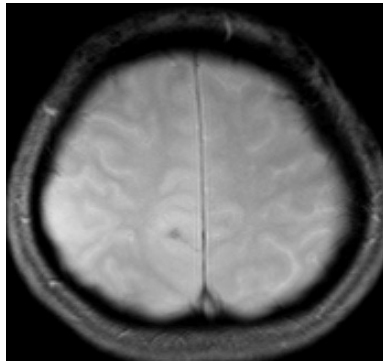
- T2 FLAIR



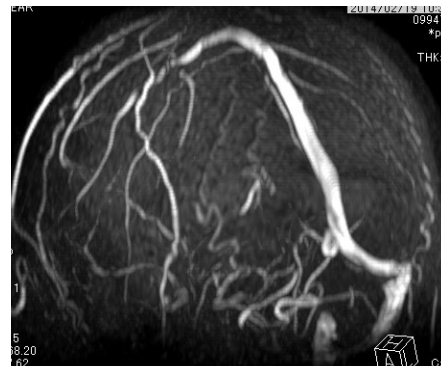Plain CT



T2\*



MR Venography



TI-201, early and delayed

